

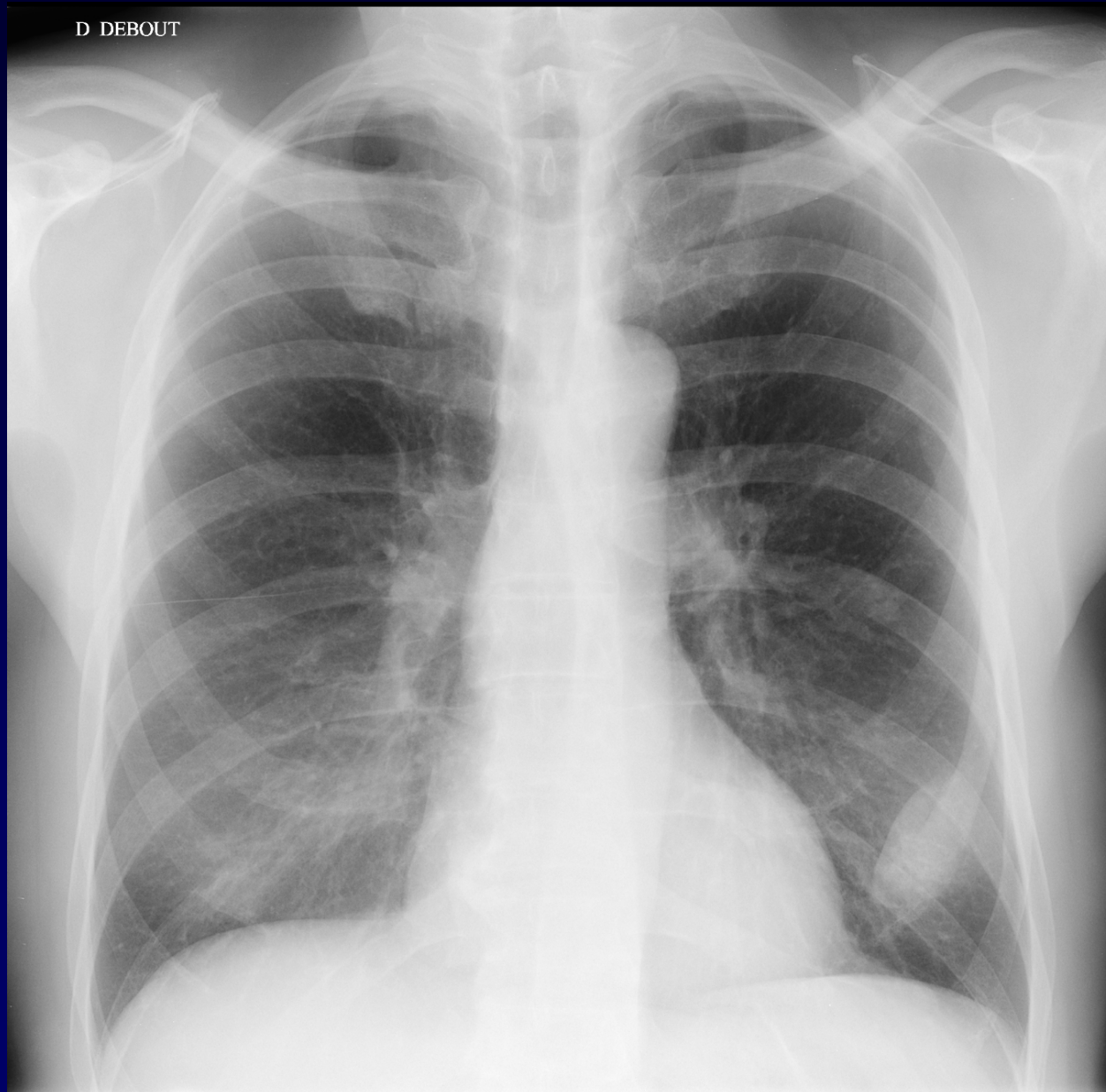
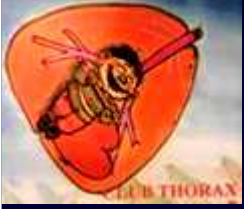
## **Dossier 2**

**M. EL HAJJAM**

**P. LACOMBE**

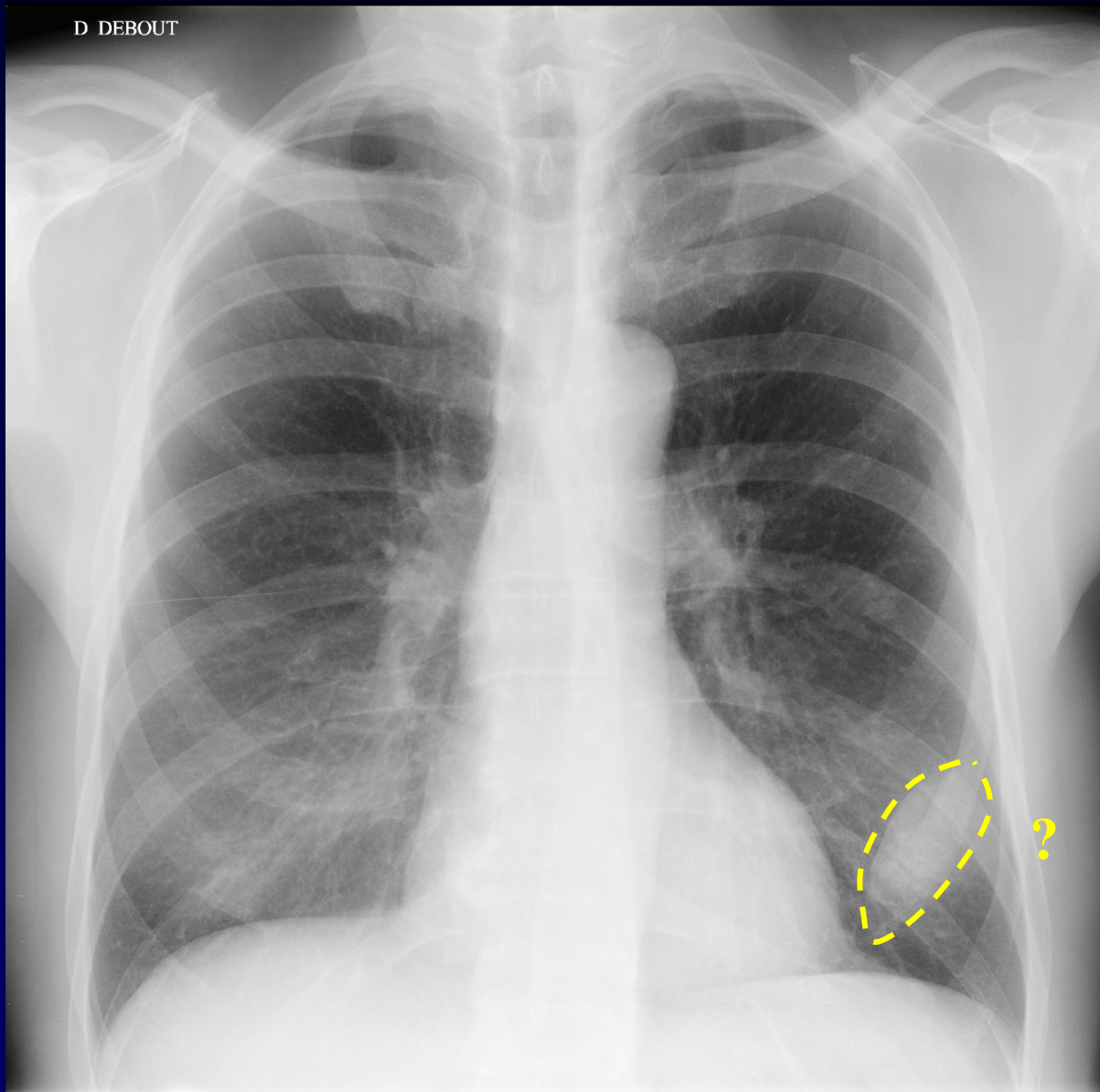
**Homme de 61 ans**

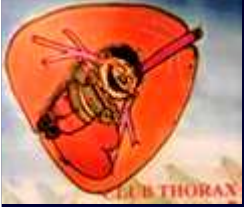**Tuméfaction douloureuse thoracique  
gauche**



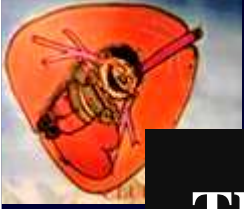

D DEBOUT

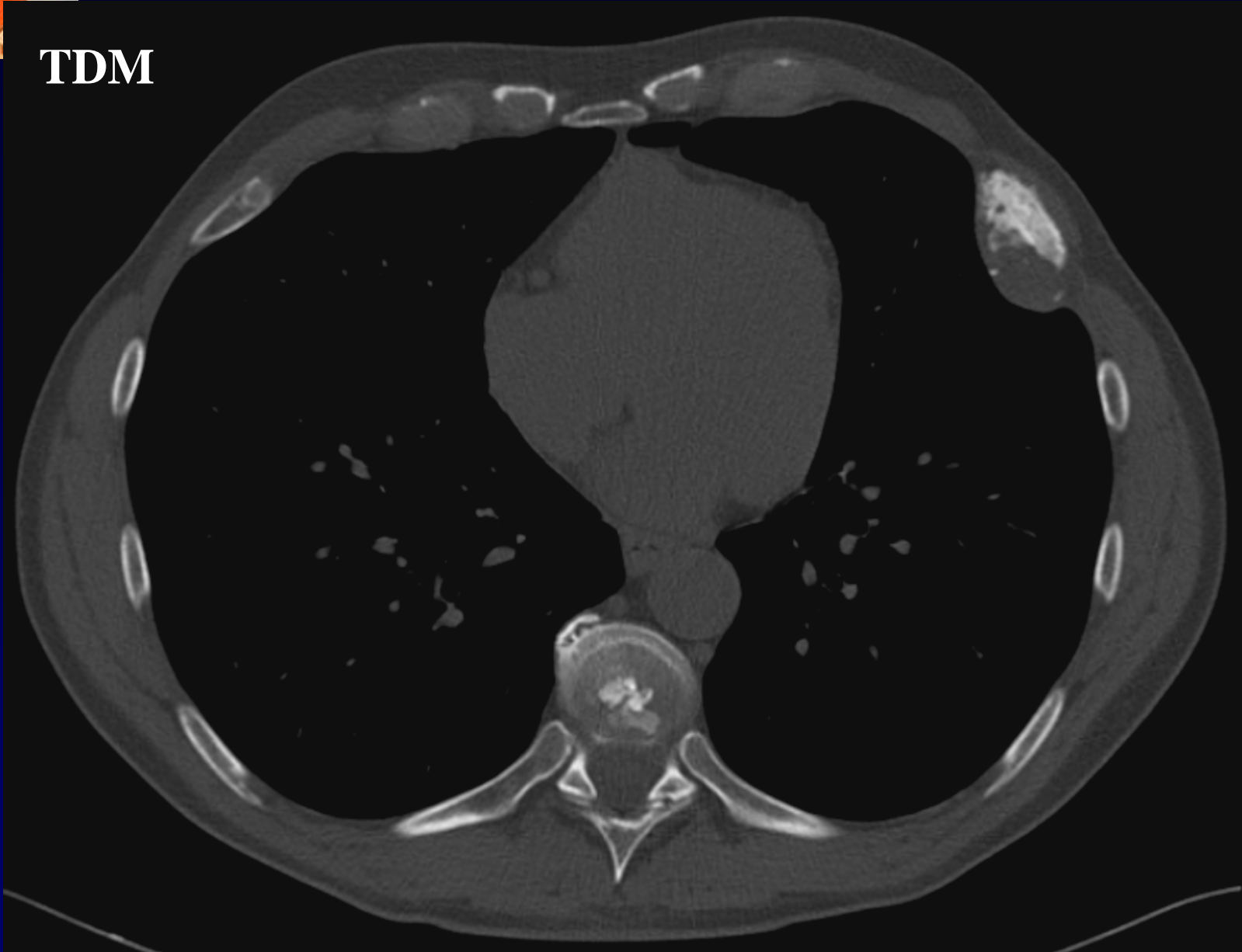


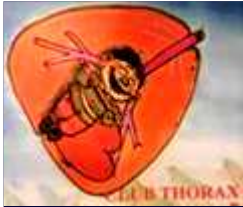

**Diagnostic ?**

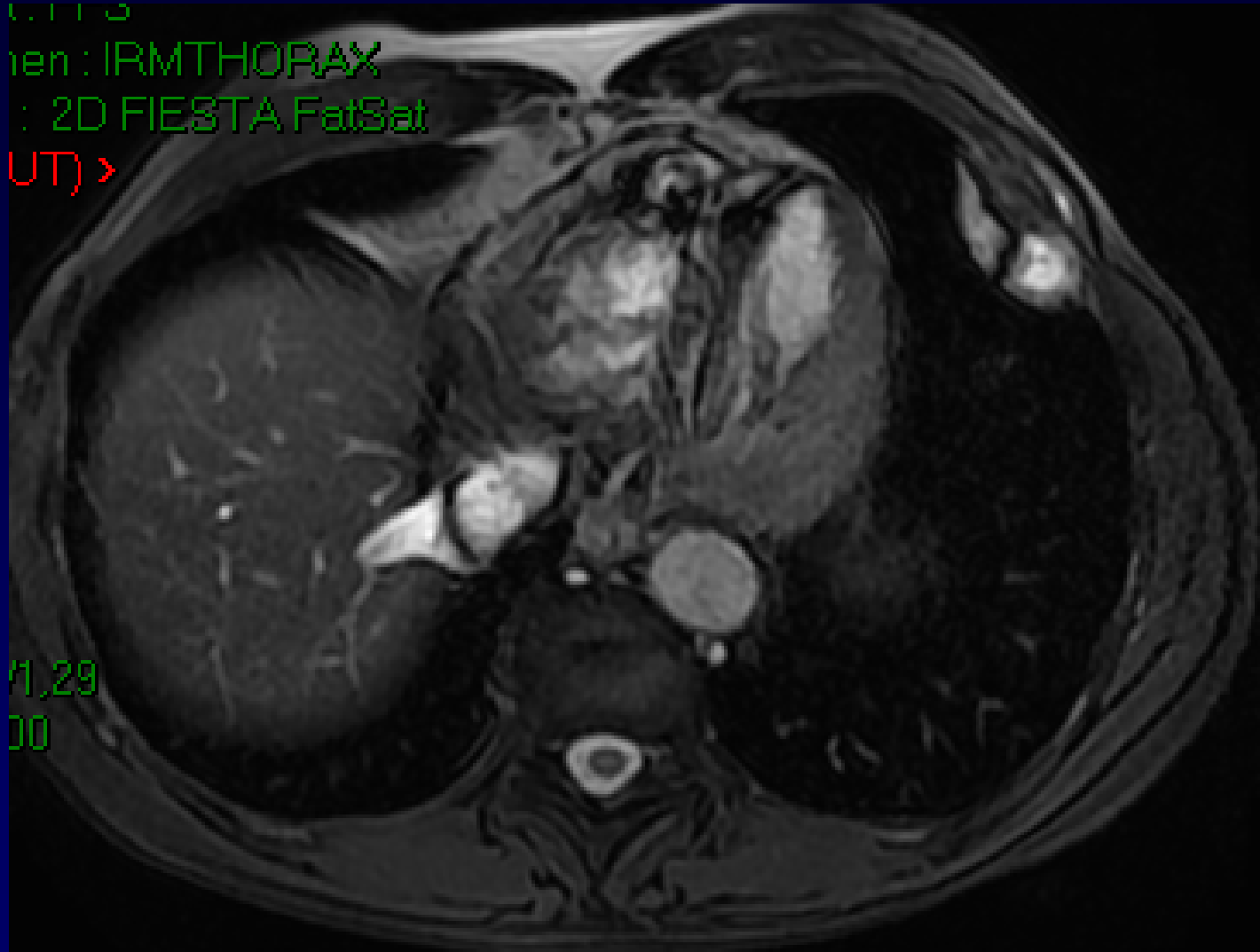


**TDM**





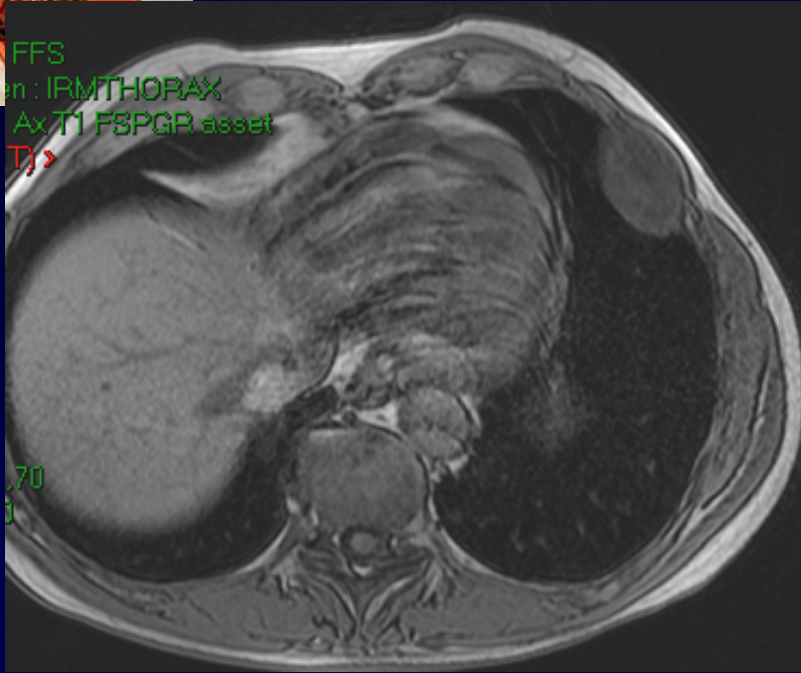
0.113  
Patient: IRMTHORAX  
Series: 2D FIESTA FatSat  
(UT) >



1,29  
00

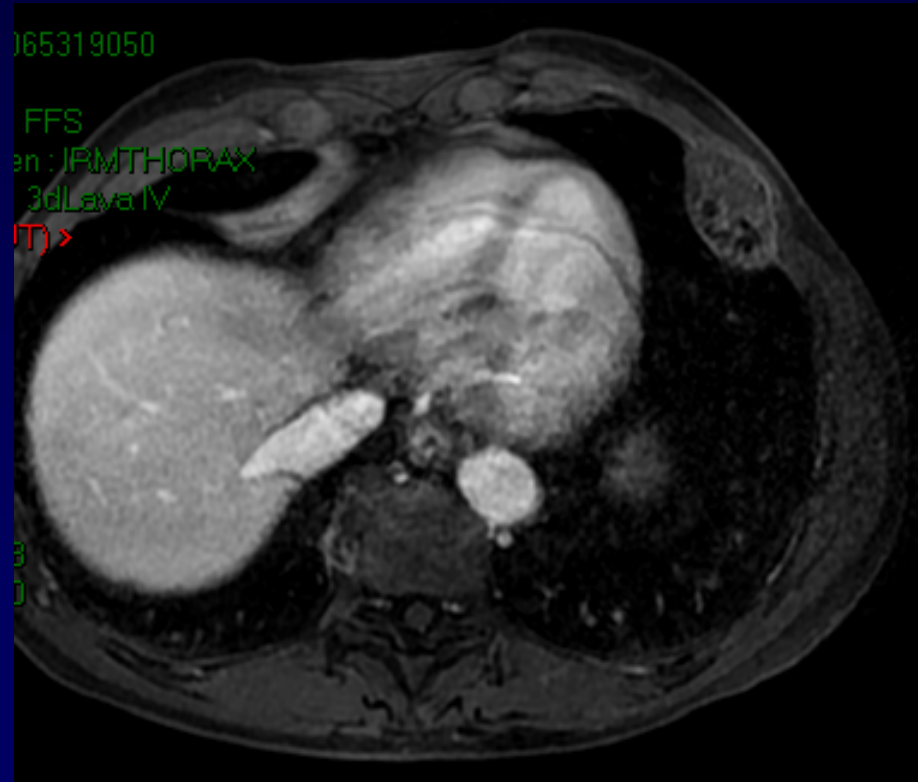


FFS  
en : IRMTHORAX  
Ax T1 FSPGR assst  
(T) >

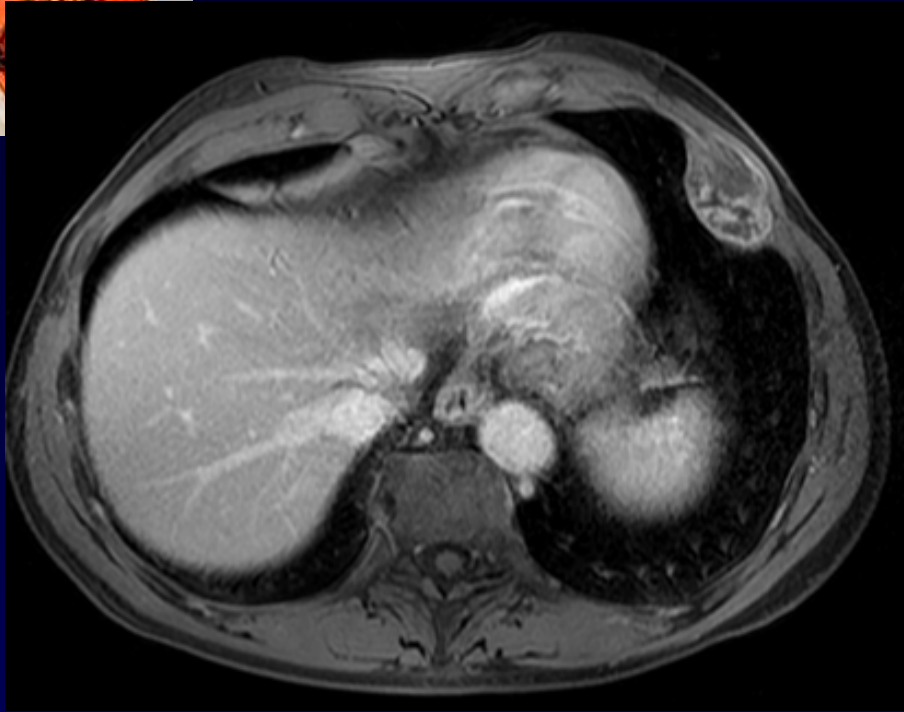


70

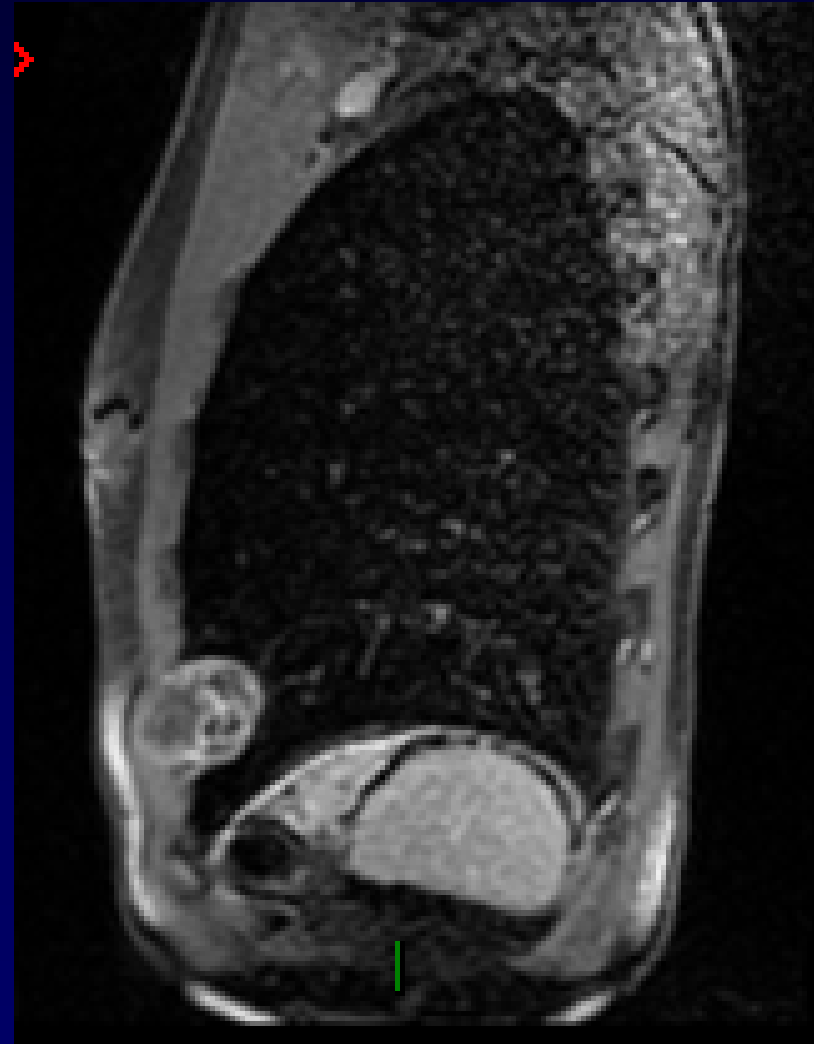
**Avant injection**



**Après injection : Gado**



**Après injection : Gado**





**Diagnostic ?**



# Diagnostic

Exérèse costale

**Chondrosarcome costal**

Codage : Paroi – Tumoral malin